

Non-steroidal and steroidal anti-inflammatory use in the context of orthodontic movement

Luégia Amorim Henriques Knop, Ricardo Lima Shintcovsk, Luciana Borges Retamoso, Jucienne Salgado Ribeiro and Orlando Motohiro Tanaka

Department of Orthodontics, Pontifical Catholic University of Paraná, Curitiba, Brazil

Correspondence to: Prof. Dr Orlando Tanaka, Graduate Dentistry Program, Department of Orthodontics, Pontifical Catholic University of Paraná, Av. Mal Deodoro, 630, 1703, 80010-912 Curitiba, Pr, Brazil. E-mail: tanakaom@gmail.com

SUMMARY The early phase of orthodontic tooth movement involves sterile acute inflammation of the periodontal ligament in response to biomechanical forces. Anti-inflammatories are pharmacologic agents used in medical and dentistry clinics. The aim of the study was to analyse the bone remodelling during orthodontic movement under non-steroidal and steroidal treatment. Male Wistar rats ($n = 90$) were randomly divided into three groups: C (control), non-steroidal anti-inflammatory drug (NSAID; potassium diclofenac), and steroidal anti-inflammatory drug (SAID; dexamethasone disodium phosphate). The animals of the C group received 0.9 per cent saline solution, the NSAID group received potassium diclofenac CATAFLAM® (5 mg/kg), and the SAID group received dexamethasone disodium phosphate DEXANIL® (2 mg/kg). Animals were sacrificed 3, 7, or 14 days after placement of the orthodontic appliance. The upper first molars were processed histologically; we quantified the blood vessels, Howship lacunae, and osteoclast-like cells present on the tension and compression sides of the periodontal ligament. Bone formation was evaluated under polarized light microscopy; 4.5 Image Pro-Plus® software calculated the percentage of immature/mature collagen present. The results showed that, in 3 and 7 days, NSAID and SAID groups presented fewer blood vessels, Howship lacunae, and osteoclast-like cells when compared to the control group. On the 7th and 14th days, there was a lower percentage of mature collagen in the SAID group ($P < 0.001$). These data demonstrate that potassium diclofenac and dexamethasone inhibit bone resorption during the initial period of orthodontic movement and that dexamethasone delays the collagen maturation process in established bone matrix.

Introduction

Orthodontic tooth movement is achieved by the remodelling of periodontal ligament and alveolar bone in response to mechanical loading (Garlet *et al.*, 2008). The transduction of mechanical forces to the cells triggers a biological response, which has been described as an aseptic inflammation because it is mediated by a variety of inflammatory cytokines (Garlet *et al.*, 2007).

Bone resorption and bone formation are parts of the remodelling process during orthodontic tooth movement. Bone is deposited on the alveolar wall on the tension side of the tooth with both heavy and light forces and the newly formed bone spicules follow the orientation of the periodontal fibre bundles. On the pressure side, with light forces, alveolar bone is resorbed directly by numerous osteoclasts in Howship's lacunae (Meikle, 2006). It has been shown that orthodontic tooth movement may be influenced by general and local administration of pharmaceutical agents (Ohkawa, 1982; Kalia *et al.*, 2004; Arias and Marquez-Orozco, 2006; de Carlos *et al.*, 2006; Bartzela *et al.*, 2009; Gonzales *et al.*, 2009).

Potassium diclofenac is a potent non-steroidal anti-inflammatory drug (NSAID; Boolbol *et al.*, 1996; Taketo, 1998a,b; Baek *et al.*, 2001). NSAIDs inhibit the two isoforms of prostaglandin H synthase [cyclooxygenase

(COX)], COX-1 and COX-2, the enzymes responsible for the formation of prostaglandins from arachidonic acid. COX-1 is expressed constitutively, while mitogens, tumour promoters, and growth factors regulate COX-2 expression (Herschman, 1996). The expression of COX-2 seems to increase angiogenesis (Tsujii *et al.*, 1998); conversely, COX inhibitors can attenuate angiogenesis (Jones *et al.*, 1999).

Dexamethasone is a potent steroidal anti-inflammatory drug (SAID) and has been demonstrated to inhibit prostaglandin and leukotrienes release through phospholipase A₂ down regulation (Fässler *et al.*, 1996; Luo *et al.*, 2003) and altered growth factors activity (e.g. transforming growth factor- β 1; Swanson *et al.*, 2006). Similarly, the drug delays gastric ulcer repair (Luo *et al.*, 2003) and decreases collagen synthesis in cutaneous wounds (Reis *et al.*, 2008).

NSAID treatment delayed bone repair (Altman *et al.*, 1995; Simon *et al.*, 2002), while the effect of glucocorticoids on the components of bone remains unclear. Pharoah and Heersche (1996) suggest that dexamethasone inhibits the formation of multinucleated osteoclasts. Hofbauer *et al.* (1999) and Swanson *et al.* (2006) report that dexamethasone increases osteoclastogenesis and stimulates bone resorption. The aim of this study was to characterize the effects of NSAID and SAID in bone remodelling due to orthodontic movement.

Materials and methods

The research was approved by the Ethics Committee for Animals of Pontifical Catholic University of Paraná (PUCPR; #69.07) according to the guiding principles outlined in the 'Care and Use of Animals'. Ninety male Wistar rats, 12 weeks of age, from the vivarium of the PUCPR, with an average weight of 350 g, were initially divided into three equal groups: C (control), NSAID (potassium diclofenac), and SAID (disodic phosphate dexamethasone; 30 animals each). Each group was composed by three subgroups, according to euthanasia day. The animals were kept in metal cages (three rats to a cage), fed a powdered diet (to prevent fracture of the orthodontic apparatus), and given water ad libitum. They were maintained on a 12/12 hour light/dark cycle at 20°C during the experimental period.

In the control group, the animals received 0.9 per cent saline solution daily; in the NSAID group, the rats received daily doses of 5 mg/kg potassium diclofenac (Cataflam®; Novartis Biociências, São Paulo-SP, Brazil) intramuscularly via; and the SAID group received daily doses of 2 mg/kg dexamethasone disodium phosphate (DEXANIL®; Ducto Indústria Farmacêutica Ltda., Anápolis-GO, Brazil), intramuscularly via (Allen *et al.*, 1998).

The orthodontic movement was produced by a nickel–titanium closed coil spring (G&H® Wire Company, Hanover, Germany) that applied a reciprocal force of 30 gF between the maxillary right first molar and maxillary central incisors, measured using a Dynamometer gauge (Dentaurum, number 1005004). The coil spring was inserted while the animal was sedated with intramuscular injection of 1.8 mg/kg ketamine (Vetanarcol®; König, Avellaneda, Argentina) and 1.1 mg/kg xylazine (Rompun®; Bayer, São Paulo, Brazil).

Animals were sacrificed on the 3rd, 7th, or 14 day with an overdose of anaesthetic; maxillae were immediately removed and fixed in 10 per cent neutral formalin for 72 hours. Specimens were decalcified for approximately 12 weeks in a 4.13 per cent EDTA aqueous solution. Transversal cuts obtained from mesiobuccal root of maxillary first molars (4 µm thickness) were cut and stained. For each specimen, 16 cuts from the alveolar crest up to the apices were obtained, where 12 were stained with hematoxylin–eosin (HE) and 4 with picrosirius.

The histological study was performed by one operator, blinded to treatment allocation. Osteoclast-like cells, active Howship lacunae, and blood vessels were quantified under $\times 400$ magnification using a light microscope. The histological criterion used to identify the osteoclast-like cells was the presence of multinuclear and eosinophilic cells on the bone surface (Arias and Marquez-Orozco, 2006).

One area from each section was selected for the evaluation of bone neoformation. The molecular organization of collagen was examined using a Leica DM LP microscope (Leica Microsystems Inc., Wetzlar, Germany; original magnification $\times 100$). Mature and immature collagen fibrils

were distinguished by the different colours of interference and the intensity of collagen birefringence. Against a black background, thick yellow–red fibres were mainly mature collagen, while fine net-like green fibrils were mainly immature collagen. An automatic image analysis system was used to measure the luminance area (SM and SI) and total area of the field (S) for mature and immature collagen fibrils. The ratio (per cent) of the luminance area to the total area of the field, SM/S and SI/S, was calculated to represent the content of mature and immature collagen fibrils, respectively.

The mean values obtained were analysed statistically. Kolmogorov–Smirnov and Levene tests evaluated treatment normality and homogeneity. For inter group comparisons, Kruskal–Wallis non-parametric multiple comparisons were used when the values were non-normal, with a level of significance at $P < 0.05$. When the values were normal and homogeneous, ANOVA/Tukey parametric comparison was used with a level of significance at $P < 0.05$.

Results

3 Days.

In the sections of these samples, we observed decreased area density of osteoclast-like cells, Howship lacunae, and blood vessels in the NSAID and SAID groups in comparison to the control group. For all variables, the SAID group demonstrated lower levels than the NSAID group, with statistically significant differences between these groups for Howship lacunae and blood vessels ($P < 0.05$; Table 1).

NSAID and SAID groups demonstrated a greater proportion of immature collagen than the control group did ($P < 0.001$). There was also a statistically significant difference ($P < 0.05$) between NSAID and SAID groups (Table 2).

7 Days.

In the sections of these samples, we observed in comparison to the control group ($P < 0.001$; Figure 1A), a decrease in osteoclast-like cells and Howship lacunae among the NSAID (Figure 1B) and SAID (Figure 1C) groups. The SAID group displayed fewer blood vessels than the NSAID group ($P < 0.05$; Table 1). In the SAID group, there was less mature collagen deposition than in the control and NSAID groups, with a statistically significant difference between the control and SAID groups ($P < 0.001$; Table 2).

14 Days.

In the sections of these samples, the SAID group demonstrated a higher capacity for inhibiting Howship lacunae and blood vessels than the NSAID group ($P < 0.01$ and $P < 0.001$, respectively; Table 1). In this period, significant difference from control ($P < 0.001$; Figure 2A) and from NSAID (Figure 2B; $P < 0.05$; Table 2) groups were observed in relation to SAID group, which still demonstrated a high percentage of immature collagen (Figure 2C).

Table 1 Mean, standard deviation (SD), and *P* values. C, control; NSAID, potassium diclofenac; SAID, dexamethasone.

Parameter	Day	C, mean \pm SD	NSAID, mean \pm SD	SAID, mean \pm SD	Inter group difference, <i>P</i>
Cells-like osteoclasts	3	5.8 \pm 1.55	1.9 \pm 0.74	0.7 \pm 0.95	*C \times NSAID, ***C \times SAID
	7	16.9 \pm 3.35	7.5 \pm 2.95	5.2 \pm 3.05	***C \times NSAID, ***C \times SAID
	14	3.3 \pm 1.06	3.1 \pm 1.45	2 \pm 2.26	NS
Howship lacunae	3	6.4 \pm 1.98	3.2 \pm 1.03	0 \pm 0	**C \times NSAID, ***C \times SAID, *NSAID \times SAID
	7	17.8 \pm 2.57	5.8 \pm 3.73	4.7 \pm 1.64	***C \times NSAID, ***C \times SAID
	14	3.9 \pm 1.98	5.3 \pm 1.95	2.1 \pm 1.59	**NSAID \times SAID
Blood vessels	3	25 \pm 3.02	14.7 \pm 2.58	7.6 \pm 1.5	*C \times NSAID, ***C \times SAID, *NSAID \times SAID
	7	7.1 \pm 1.45	16.8 \pm 3.01	3.7 \pm 2.87	***C \times NSAID, *C \times SAID, *NSAID \times SAID
	14	3.1 \pm 1.98	14.7 \pm 3.4	1.6 \pm 2.17	*C \times NSAID, * **NSAID \times SAID

NS, non-significant.

Significant level **P* < 0.05, ***P* < 0.01, ****P* < 0.001.**Table 2** Mean, standard deviation (SD), and *P* values. C, control; NSAID, potassium diclofenac; SAID, dexamethasone.

Parameter	Day	C, mean \pm SD	NSAID, mean \pm SD	SAID, mean \pm SD	Inter group difference, <i>P</i>
% Mature collagen	3	10.78 \pm 3.73	5.5 \pm 2.7	2.5 \pm 1.08	***C \times NSAID, ***C \times SAID, *NSAID \times SAID
	7	39.55 \pm 4.27	29.8 \pm 8.13	13.9 \pm 13.24	***C \times SAID
	14	100 \pm 0	96.9 \pm 2.08	49.09 \pm 16.08	***C \times SAID, *NSAID \times SAID
% Immature collagen	3	89.22 \pm 3.73	94.5 \pm 2.07	97.5 \pm 1.08	***C \times NSAID, ***C \times SAID, *NSAID \times SAID
	7	60.44 \pm 4.27	70.2 \pm 8.13	86.91 \pm 13.24	***C \times SAID
	14	0 \pm 0	3.1 \pm 2.08	50.91 \pm 16.08	***C \times SAID, *NSAID \times SAID

NS, non-significant.

Significant level **P* < 0.05, ***P* < 0.01, ****P* < 0.001.

Discussion

Cytokines are essential for evoke subsequent biological events and bone remodelling to accommodate movement of the tooth (Sari *et al.*, 2004). According to Krishnan and Davidovitch (2006), arachidonic acid metabolites play an important role in the bone remodelling process during orthodontic tooth movement. The arachidonic acid release is metabolized by A2 phospholipase via two distinct pathways—the cyclooxygenase pathway that produces prostaglandins and the lipooxygenase pathway that leads to the release of leucotrienes. Prostaglandins are associated with higher numbers of osteoclasts (Lee *et al.*, 2006), as well as stimulating osteoblastic differentiation (Krishnan and Davidovitch, 2006).

The role of cytokines and prostaglandins in periodontal remodelling has been previously documented. Saito *et al.* (1990) showed that the bone resorption of periodontal ligament cells was induced by prostaglandin E2 (PGE2) *in vitro*. Furthermore, local application of PGE2 to teeth under orthodontic forces resulted in increased tooth movement (Koide *et al.*, 1995) at a cellular level. Proinflammatory cytokines [e.g. tumour necrosis factor- α or interleukin-1 β] induce the cyclooxygenase-mediated production of prostaglandins in endothelial cells (Maier *et al.*, 1990).

It has been described that potassium diclofenac inhibits COX-1 and COX-2, the enzymes responsible for the formation of prostaglandins from arachidonic acid, while dexamethasone inhibits prostaglandin and leucotriene

release through phospholipase A₂ downregulation (Fässler *et al.*, 1996; Luo *et al.*, 2003).

Our investigation suggests that prostaglandin inhibition by anti-inflammatory drugs triggers a cascade of events following the application of orthodontic force. We observed reduced numbers of osteoclast-like cells, Howship lacunae, and blood vessels throughout all periods studied in the NSAID and SAID groups. The influence of NSAIDs on orthodontic movement is supported by de Carlos *et al.* (2006), who evaluated that two local injections of potassium diclofenac (10 mg/kg) completely eliminated first molar movement in rats.

All variables examined were more inhibited in the SAID group as compared to the NSAID group. At 3 and 14 days, there was a statistically significant difference in the number of Howship lacunae, with *P* < 0.05 and *P* < 0.01, respectively.

At each time-point, we observed that blood vessels in the NSAID group were not inhibited as strongly as in the SAID group. Vascularity and permeability increased, resulting in the release of biomechanical signal molecules and osteoclast precursor migration (Krishnan and Davidovitch, 2006). Roberts and Hartsfield (2004) affirm that new osteoblast precursors are recruited from the population of pericytes around periodontal ligament capillaries. We suggest that inhibiting blood vessels by dexamethasone until day 14, resulted in fewer osteoclast-like cells, reducing Howship lacunae number and consequently bone resorption.

When comparing scientific studies in the literature, we observed that glucocorticoids may produce antagonistic

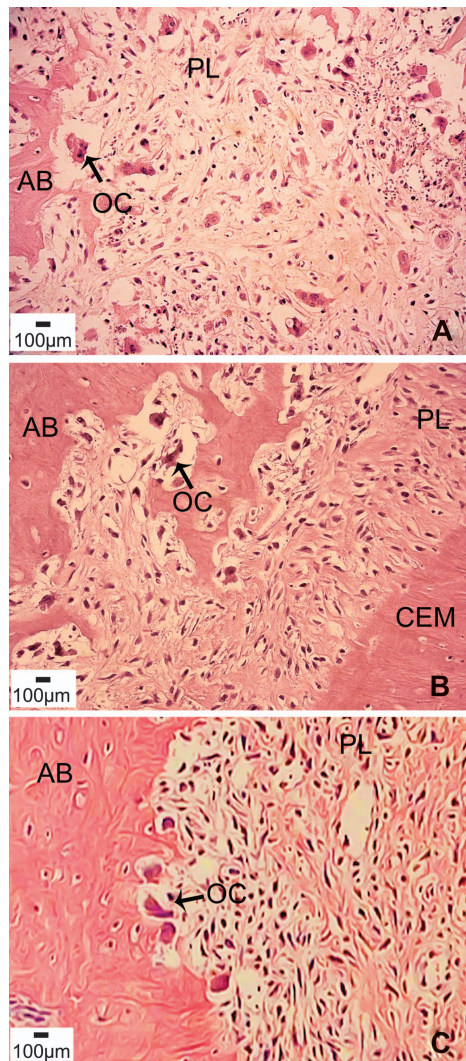


Figure 1 First molar mesiobuccal root photomicrographs (haematoxylin and eosin). (A) Compression side from control group, 7 days. (B) Compression side from non-steroidal anti-inflammatory drug group, 7 days. (C) Compression side from steroidal anti-inflammatory drug group, 7 days (original magnification $\times 400$). AB, alveolar bone; CEM, cementum; PL, periodontal ligament; OC, osteoclast-like cell.

effects upon bone resorption during tooth movement. Ashcraft *et al.* (1992) evaluated the effect of cortisone acetate on orthodontic movement in rabbits and observed a decrease in the mean incremental active tooth movement. Ong *et al.* (2000) observed lower tartrate-resistant acid phosphatase-positive cells on the compression side after prednisolone administration, while Hofbauer *et al.* (1999) and Swanson *et al.* (2006) affirm that corticosteroids stimulate *in vitro* bone resorption by osteoclast activity and/or formation increased. Kalia *et al.* (2004) used methylprednisolone 8 mg/kg/day under chronic and acute treatment and observed different results between the groups. In the acute, it was observed reduction on resorption percentage, while in the chronic, the tooth movement rate increased, due to secondary hyperparathyroidism.

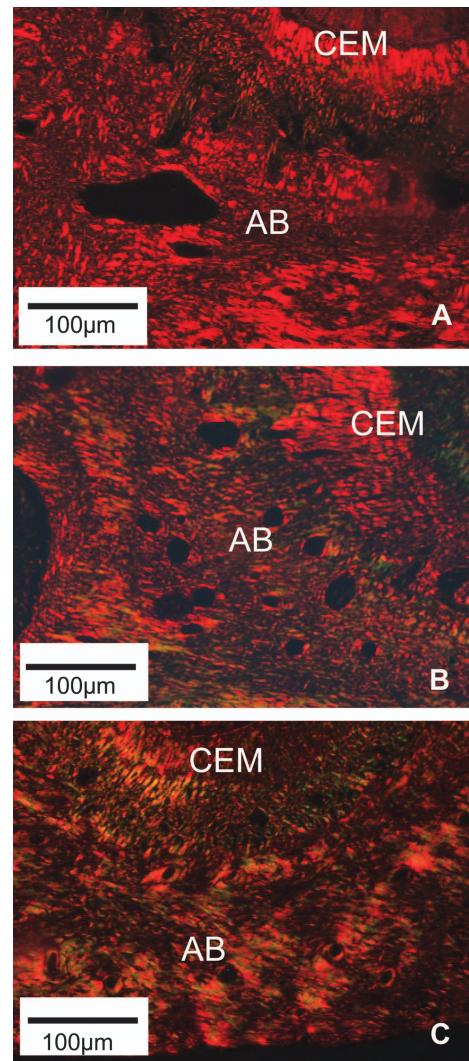


Figure 2 First molar mesiobuccal root photomicrographs (picrosirius). (A) Tension side from control group, 14 days. (B) Tension side from non-steroidal anti-inflammatory drug group, 14 days. (C) Tension side from steroidal anti-inflammatory drug group, 14 days (original magnification $\times 100$). AB, alveolar bone; CEM, cementum.

For Ong *et al.* (2000), these differences may be explained by variations within the animal species studied, forces used to move teeth, duration of experiment, dosage, duration of drug administration, and potency of the steroid used. We aimed to analyse bone neoformation on the tension side by polarized microscopy. This method allows us to detect mature and immature collagen, as well as correlate the three-dimensional distribution of collagen fibres with a particular stage of bone formation. The collagen colour and birefringence vary according to polymerization degree, reflecting fibre age and diameter; the collagen is initially deposited as thin fibrils that aggregate until they form larger fibres or bundles (Garavello-Freitas *et al.*, 2003).

At all time-points, the NSAID and SAID groups presented lower mature collagen deposition than the control group. At 3 and 14 days, the SAID group exhibited impaired

development of mature collagen as compared to the NSAID group ($P < 0.05$).

Orthodontic movement involves a complex chain of events (Krishnan and Davidovitch, 2006); we suggest that inhibiting some initial stage, for example, neovascularization, osteoblast differentiation, or collagen synthesis, may delay other stages, such as collagen maturation during bone neoformation.

The present study recommends further research into orthodontic tooth movement in patients receiving potassium diclofenac and dexamethasone administration. It has been proposed that clinical appointments should be scheduled with longer intervals as bone turnover will be delayed. In summary, this study demonstrated that inflammation is essential to orthodontic movement and the use of glucocorticoids in orthodontic patients may delay the bone remodelling process.

References

- Allen D G, Pringle J K, Smith D A 1998 Handbook of veterinary drugs. Lippincott-Raven, Philadelphia
- Altman R D, Latta L L, Keer R, Renfree K, Hornicek F J, Banovac K 1995 Effect of nonsteroidal anti-inflammatory drugs on fracture healing: a laboratory study in rats. *Journal of Orthopaedic Trauma* 9: 393–400
- Arias O R, Marquez-Orozco M C 2006 Aspirin, acetaminophen, and ibuprofen: their effects on orthodontic tooth movement. *American Journal of Orthodontics and Dentofacial Orthopedics* 130: 364–370
- Ashcraft M B, Southard K A, Tolley E A 1992 The effect of corticosteroid-induced osteoporosis on orthodontic tooth movement. *American Journal of Orthodontics and Dentofacial Orthopedics* 102: 310–319
- Baek S J, Kim K S, Nixon J B, Wilson L C, Eling T E 2001 Cyclooxygenase inhibitors regulate the expression of a TGF- β superfamily member that has proapoptotic and antitumorigenic activities. *Molecular Pharmacology* 59: 901–908
- Bartzela S, Türp J C, Mutschall E, Maltha J C 2009 Medication effects on the rate of orthodontic tooth movement: a systematic literature review. *American Journal of Orthodontics and Dentofacial Orthopedics* 135: 16–26
- Boolbol S K *et al.* 1996 Cyclooxygenase-2 overexpression and tumor formation are blocked by sulindac in a murine model of familial adenomatous polyposis. *Cancer Research* 56: 2556–2560
- de Carlos F, Cobo J, Diaz-Esnal B, Arguelles J, Vijande M, Costales M 2006 Orthodontic tooth movement after inhibition of cyclooxygenase-2. *American Journal of Orthodontics and Dentofacial Orthopedics* 129: 402–406
- Fässler R, Sasaki T, Timpl R, Chu M L, Werner S 1996 Differential regulation of fibulin, tenascin-C, and nidogen expression during wound healing of normal and glucocorticoid-treated mice. *Experimental Cell Research* 222: 111–116
- Garavello-Freitas I, Baranauskas V, Joazeiro P P, Padovani C R, Dal Pai-Silva M, Da Cruz-Höfling M A 2003 Low-power laser irradiation improves histomorphometrical parameters and bone matrix organization during tibia wound healing in rats. *Journal of Photochemical and Photobiology* 70: 81–89
- Garlet T P, Coelho U, Repeke C E, Silva J S, Cunha F de Q, Garlet G P 2008 Differential expression of osteoblast and osteoclast chemotactic factors in compression and tension sides during orthodontic movement. *Cytokine* 42: 330–335
- Garlet T P, Coelho U, Silva J S, Garlet G P 2007 Cytokine expression pattern in compression and tension sides of the periodontal ligament during orthodontic tooth movement in humans. *European Journal of Oral Science* 115: 355–362
- Gonzales C *et al.* 2009 Effects of steroidal and non-steroidal drugs on tooth movement and root resorption in the rat molar. *Angle Orthodontist* 79: 715–726
- Herschman H R 1996 Prostaglandin synthase 2. *Biochimica et Biophysica Acta* 1299: 125–140
- Hofbauer L C *et al.* 1999 Stimulation of osteoprotegerin ligand and inhibition of osteoprotegerin production by glucocorticoids in human osteoblastic lineage cells: potential paracrine mechanisms of glucocorticoid-induced osteoporosis. *Endocrinology* 140: 4382–4389
- Jones M K *et al.* 1999 Inhibition of angiogenesis by nonsteroidal anti-inflammatory drugs: insight into mechanisms and implications for cancer growth and ulcer healing. *Nature Medicine* 5: 1418–1423
- Kalia S, Melsen B, Verna C 2004 Tissue reaction to orthodontic tooth movement in acute and chronic corticosteroid treatment. *Orthodontics and Craniofacial Research* 7: 26–34
- Koide M, Suda S, Saitoh S, Ofuji Y, Suzuki T, Voshie H 1995 In vivo administration of IL-1 β accelerates alveolar bone resorption in rats. *Journal of Oral Pathology and Medicine* 24: 420–434
- Krishnan V, Davidovitch Z 2006 Cellular, molecular, and tissue level reactions to orthodontic force. *American Journal of Orthodontics and Dentofacial Orthopedics* 129: 1–32
- Lee H J *et al.* 2006 Roles of p38 and ERK MAP kinases in IL-8 expression in TNF- α - and dexamethasone-stimulated human periodontal ligament cells. *Cytokine* 35: 67–76
- Luo J C *et al.* 2003 Non-ulcerogenic dose of dexamethasone delays gastric ulcer healing in rats. *Journal of Pharmacology and Experimental Therapeutics* 307: 692–698
- Maier J A, Hla T, Maciag T 1990 Cyclooxygenase is an immediate early gene induced by interleukin-1 in human endothelial cells. *Journal of Biological Chemistry* 265: 10805–10808
- Meikle M C 2006 The tissue, cellular, and molecular regulation of orthodontic tooth movement: 100 years after Carl Sandstedt. *European Journal of Orthodontics* 28: 221–240
- Ohkawa S 1982 Effects of orthodontic forces and anti-inflammatory drugs on the mechanical strength of the periodontium in the rat mandibular first molar. *American Journal of Orthodontics* 81: 498–502
- Ong C K, Walsh L I, Harbrow D, Taverne A A, Symons A L 2000 Orthodontic tooth movement in the prednisolone-treated rat. *Angle Orthodontist* 70: 118–125
- Pharoah M J, Heersche J N 1996 Dexamethasone inhibits formation of osteoclast-like cells in bone-marrow cultures. *Journal of Dental Research* 65: 1006–1009
- Reis S R, Medrado A P, Marchionni A M, Figueira C, Fracassi L D, Knop L A 2008 Effect of 670-nm laser therapy and dexamethasone on tissue repair: a histological and ultrastructural study. *Photomedicine and Laser Surgery* 29: 307–313
- Roberts W E, Hartsfield J K 2004 Bone development and function: genetic and environmental mechanisms. *Seminars in Orthodontics* 10: 100–122
- Saito S, Rosol T J, Saito M, Ngan P W, Shanfeld J, Davidovitch Z 1990 Bone resorbing activity and PGE produced by human periodontal ligament in vitro. *Journal of Bone and Mineral Research* 5: 1013–1018
- Sari E, Olmez H, Gurton U 2004 Comparison of some effects of acetylsalicylic acid and rofecoxib during orthodontic tooth movement. *American Journal of Orthodontics and Dentofacial Orthopedics* 125: 310–315
- Simon A M, Manigrasso M B, O'connor J P 2002 Cyclo-oxygenase 2 function is essential for bone fracture healing. *Journal of Bone and Mineral Research* 17: 963–976
- Swanson C, Lorentzon M, Conaway H H, Lerner U H 2006 Glucocorticoid regulation of osteoclast differentiation and expression of receptor activator of nuclear factor- κ B (NF- κ B) ligand, osteoprotegerin, and receptor activator of NF- κ B in mouse calvarial bones. *Endocrinology* 147: 3613–3622
- Taketo M M 1998a Cyclooxygenase-2 inhibitors in tumorigenesis (part I). *Journal of the National Cancer Institute* 90: 1529–1536
- Taketo M M 1998b Cyclooxygenase-2 inhibitors in tumorigenesis (part II). *Journal of the National Cancer Institute* 90: 1609–1620
- Tsuji M, Kawano S, Tsuji S, Sawaoka H, Hori M, Dubois R N 1998 Cyclooxygenase regulates angiogenesis induced by colon cancer cells. *Cell* 93: 705–716